
Development and validation of a noninvasive 2-gene molecular assay for cutaneous melanoma



Pedram Gerami, MD,^a Zuxu Yao, PhD,^b David Polsky, MD, PhD,^{c,d} Burkhard Jansen, MD,^b Klaus Busam, MD,^e Jonhan Ho, MD,^f Mary Martini, MD,^a and Laura K. Ferris, MD, PhD^f
Chicago, Illinois; La Jolla, California; New York, New York; and Pittsburgh, Pennsylvania

Background: Clinical and histopathologic assessment of pigmented skin lesions remains challenging even for experts. Differentiated and accurate noninvasive diagnostic modalities are highly desirable.

Objective: We sought to provide clinicians with such a tool.

Methods: A 2-gene classification method based on LINC00518 and preferentially expressed antigen in melanoma (PRAME) gene expression was evaluated and validated in 555 pigmented lesions (157 training and 398 validation samples) obtained noninvasively via adhesive patch biopsy. Results were compared with standard histopathologic assessment in lesions with a consensus diagnosis among 3 experienced dermatopathologists.

Results: In 398 validation samples (87 melanomas and 311 nonmelanomas), LINC00518 and/or PRAME detection appropriately differentiated melanoma from nonmelanoma samples with a sensitivity of 91% and a specificity of 69%. We established LINC00518 and PRAME in both adhesive patch melanoma samples and underlying formalin fixed paraffin embedded (FFPE) samples of surgically excised primary melanomas and in melanoma lymph node metastases.

Limitations: This technology cannot be used on mucous membranes, palms of hands, and soles of feet.

Conclusions: This noninvasive 2-gene pigmented lesion assay classifies pigmented lesions into melanoma and nonmelanoma groups and may serve as a tool to help with diagnostic challenges that may be inherently linked to the visual image and pattern recognition approach. (*J Am Acad Dermatol* 2017;76:114-20.)

Key words: biopsy; gene expression; histopathology; LINC00518; melanoma; noninvasive; preferentially expressed antigen in melanoma.

The visual assessment of pigmented skin lesions remains a challenge even for experienced dermatologists and pigmented lesion experts because of inherent limitations of image

recognition. Tools such as dermoscopy or computer-aided image analysis of skin lesions can reduce but not overcome these inherent limitations.¹ This challenge continues after a decision has been

From the Department of Dermatology, Northwestern University, Chicago^a; DermTech Inc, La Jolla^b; Ronald O. Perleman Departments of Dermatology^c and Pathology,^d New York University School of Medicine, New York University Langone Medical Center; Department of Pathology, Memorial Sloan-Kettering Cancer Center, New York^e; and Department of Dermatology, University of Pittsburgh.^f

Sponsored by DermTech Inc (La Jolla, CA) and supported by the IDP Foundation (Chicago, IL).

Disclosure: Drs Gerami, Polsky, and Ferris serve as consultants to DermTech Inc. Drs Yao and Jansen are employees of DermTech Inc. Drs Busam, Ho, and Martini have no conflicts of interest to declare.

Presented as a late-breaking presentation (abstract 3816) at the 74th Annual Meeting of the American Academy of Dermatology in Washington, DC, on March 4-8, 2016.

Accepted for publication July 19, 2016.

Reprint requests: Pedram Gerami, MD, Department of Dermatology, Northwestern University, 676 N St Clair St, Suite 1765, Chicago, IL 60611. E-mail: pgerami1@nm.org.

Published online October 1, 2016.

0190-9622

© 2016 by the American Academy of Dermatology, Inc. Published by Elsevier, Inc. This is an open access article under the CC BY-NC-ND license (<http://creativecommons.org/licenses/by-nc-nd/4.0/>).

<http://dx.doi.org/10.1016/j.jaad.2016.07.038>

made to invasively biopsy an atypical pigmented lesion to obtain additional information. The well-established gold standard of routine dermatopathology used on the overwhelming majority of cases again focuses on structural disorder and image along with pattern recognition.² Immunohistochemistry can provide additional information but does not introduce a diagnostic paradigm shift.³

Numerous studies have shown that molecular analysis techniques such as fluorescence in situ hybridization, comparative genomic hybridization, and messenger RNA expression profiling of surgically obtained specimens can help predict the behavior of melanocytic neoplasms including melanoma beyond traditional methods.^{4,5} However, current molecular techniques depend on tissue obtained via invasive biopsies. A simpler yet accurate and noninvasive diagnostic tool to support clinical decisions appears highly attractive and desired by both health care providers and patients.

Our earlier work demonstrated feasibility of noninvasive gene expression analysis for melanoma.^{6,7} The current study on 555 pigmented lesions, including 167 melanomas, sought to demonstrate and validate that the expression of LINC00518 (LINC) and preferentially expressed antigen in melanoma (PRAME) can accurately classify pigmented lesions using a simple 2-gene detection methodology.

METHODS

Subjects and study design

Participants were 18 years of age or older and had a clinically suspicious pigmented lesion of at least 4 mm in diameter. Participants were excluded if they had used topical medications or systemic steroids within 30 days before the study or had a generalized skin disorder unrelated to skin cancer. All multicenter study protocols were approved by a central institutional review board (Western International Review Board Copernicus Group, WCG) along with the institutional review boards at clinical test sites. A total of 28 sites in the United States, Europe, and Australia were included. All pigmented skin lesions suspicious for melanoma were selected by dermatologists experienced in pigmented lesion

management. Cases of obvious nodular melanoma or cases suspicious for nodular melanoma were not included. The study includes a training set of samples for development of the classification method based on LINC and PRAME gene expression detection and an independent validation set of samples for validation of target gene expression

and classification methodology (Table I). Additional information about the sample sets is provided in Supplemental Tables I and II (available at <http://www.jaad.org>).

Noninvasive adhesive patch and conventional surgical biopsies

Each sample collection involved a 2-step process, a noninvasive adhesive patch biopsy followed by a conventional surgical biopsy of the same pigmented lesion. For the adhesive patch biopsy, a class I device skin biopsy kit (DermTech Inc, La

Jolla, CA) was used following the manufacturer's instructions. All adhesive patch samples in this study were frozen and stored at -80°C before total RNA extraction. Conventional surgically biopsied samples were routinely processed and assessed by a primary reader and a panel of 3 expert dermatopathologists who provided a consensus diagnosis to assess the performance of the 2-gene PLA (pigmented lesion assay). The experts did not unanimously agree on a melanoma diagnosis in 11% of cases, which were excluded from this validation study because no unequivocal gold standard reference diagnosis could be established. The expert panel diagnosis was also compared with the primary reader's diagnosis to assess the sensitivity and specificity of the primary histopathology assessment.

Gene expression analysis on adhesive patch biopsied samples

Adhesive patches were macrodissected to separate lesional tissue from surrounding normal tissue. Total RNA was isolated from the recovered lesional tissue using a modified PicoPure procedure (Life Technologies, Foster City, CA) and reverse transcribed to complementary DNA using SuperScript VILO complementary DNA synthesis kits (Thermo Fisher Scientific, Pittsburgh, PA). The resulting complementary DNA was subsequently used for target

CAPSULE SUMMARY

- The potential of gene expression analysis to differentiate pigmented skin lesions is increasingly recognized.
- LINC00518 and/or preferentially expressed antigen in melanoma gene expression differentiates primary melanomas from nonmelanoma lesions with a negative predictive value greater than 99%.
- The described gene expression test is a novel tool to support clinicians in their efforts to accurately diagnose primary cutaneous melanomas.

Abbreviations used:

LINC:	LINC00518
PCR:	polymerase chain reaction
PRAME:	preferentially expressed antigen in melanoma
qRT:	quantitative real-time
SSM:	superficial spreading melanoma

gene expression analysis with quantitative real-time (qRT)-polymerase chain reaction (PCR) on an ABI7900 PCR system (Life Technologies). Each qRT-PCR reaction used 3 pg of total RNA, in duplicate, in 20- μ L volume on 384-well PCR reaction plates using predesigned gene-specific TaqMan probe chemistries (Life Technologies). An averaged cycle threshold value of the duplicate measurements was used in the analysis. Gene expression was considered detected if the quantitative polymerase chain reaction yielded an amplification curve and a measurable cycle threshold value, or not detected if the reaction yielded an undetermined cycle threshold value (amplification curve never above detection threshold). In addition to the 2 target genes, human β -actin was used as an internal control.

Gene expression analysis in surgically biopsied samples and in patient-derived xenografts

We also analyzed 6 FFPE samples of primary melanomas underlying the lesional skin harvested via adhesive patches, 5 melanoma lymph node metastases, and 6 patient-derived xenografts of metastatic melanomas⁸ to assess and correlate expression of LINC and PRAME. Total RNA was isolated from the FFPE tissue with PureLink FFPE total RNA isolation kits (Invitrogen, Carlsbad, CA) following the manufacturer's instruction, and used in gene expression measurements following the qRT-PCR procedures described above.

Statistical analysis

The genes used in this study were previously reported as part of a larger classification signature.⁸ Sensitivity, specificity, negative predictive value, and area under the curve—receiver operating characteristic curve were calculated using R for the training, validation, and validation subgroup sets (R Core Team, 2011). Comparison of LINC and PRAME gene expression in xenografts was performed using Excel (Microsoft, Redmond, WA).

RESULTS

The adhesive patch used to noninvasively obtain skin biopsy samples is shown in Fig 1; it collects

Table 1. Dermatopathologic diagnoses of validation set samples

	Training set (N = 157)	Validation set (N = 398)
Melanomas	80	87
Invasive melanomas	59	53
In situ melanomas	18	19
Invasive/in situ melanomas*	3	15
Nevi	67	253
Conventional nevi	20	48
Dysplastic nevi	41	177
Conventional/dysplastic nevi [†]	6	28
Other nonmelanoma diagnoses [‡]	10	58

The training set (n = 157) set included 37 lesions on extremities, 28 on head and neck, and 92 on the trunk (92 men and 65 women, age range 18-97 y, median age 48 y, median melanoma thickness 0.55 mm). The validation set (n = 398) included 97 lesions on extremities, 53 on head and neck, and 248 on the trunk (218 men, 179 women, 1 no gender reported). The age range in the validation set was 19-97 y (median age 49 y). The median melanoma thickness in the validation set was 0.45 mm.

*Diagnosed as melanoma by 3 dermatopathologists without full agreement on the invasive/in situ nature of the sample.

[†]Diagnosed as nevus by 3 dermatopathologists without full agreement on presence or absence of dysplasia.

[‡]Includes seborrheic keratosis, lentigo simplex, basal cell carcinoma, and fibrosis.

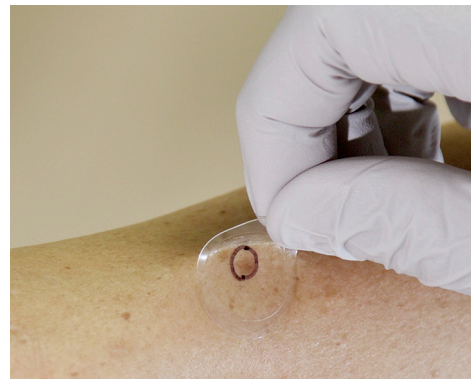

Fig 1. Noninvasive adhesive patch skin biopsy.

stratum corneum tissue samples containing gene expression information from the underlying pigmented lesion. Of adhesive patch biopsied samples, 86% yielded sufficient amounts of total RNA for gene expression analysis, leading to a quantity-not-sufficient rate of 14%.

Two sets of clinical samples (training and validation sets) were used for this 2-gene PLA validation study. The training set included 157 samples (80 melanomas and 77 nonmelanomas) and the validation set included a total of 398 samples (87 melanomas and 311 nonmelanomas). In all, 57 melanomas were superficial spreading melanoma

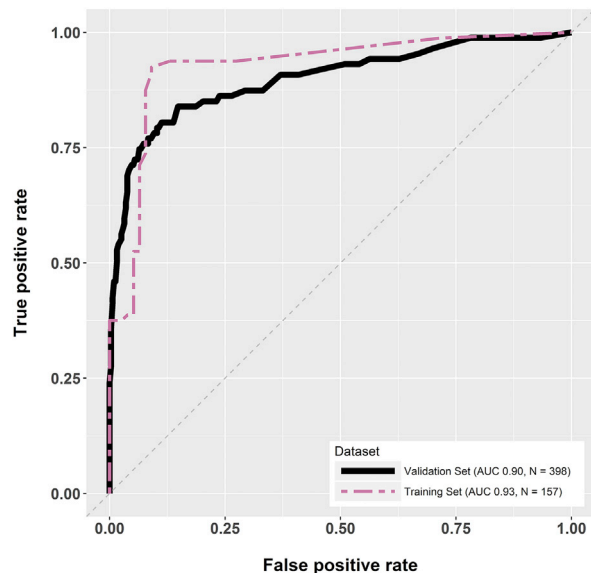


Fig 2. Receiver operating characteristic curves demonstrating the PLA's potential to differentiate primary cutaneous melanoma samples from nonmelanoma samples (primarily atypical nevi) based on LINC00518 and/or preferentially expressed antigen in melanoma detection. AUC, Area under the curve.

(SSM) type, 13 were lentigo maligna or lentigo maligna melanoma type, and 15 had hybrid features of SSM and lentigo maligna melanoma. The median thickness of invasive melanomas for the training set and the validation set was 0.55 mm and 0.45 mm, respectively. Over two thirds of all nevi were considered atypical. Table I shows the concordance diagnoses rendered by a panel of 3 expert dermatopathologists that were used as reference points to assess test performance. Of samples, 11% were excluded because of discordant histopathologic diagnosis.

Area under the curve values for the training set and the validation set samples were 0.93 and 0.90, respectively (Fig 2). The 2-gene PLA on training set samples yielded a sensitivity of 91% and a specificity of 53% (Table II). In the validation set, the sensitivity and specificity were 91% and 69%, respectively (Table III). In the set of 203 serially collected samples, the sensitivity was 79% and the specificity 80%. Melanoma samples were representative of cases generally seen in clinical practice and included invasive SSM, SSM in situ, lentigo malignas, and others with thin SSM being the largest subgroup (57%). For melanoma samples in the validation set, the test sensitivity for invasive melanomas and in situ melanomas was 94% and 89%, respectively. The calculated negative predictive value exceeded 99% (based on 7% prevalence).

Although validating the importance of LINC and PRAME gene expression in adhesive patch biopsy samples of primary melanomas was a clear focus, we also sought to establish that our targets are detectable in FFPE blocks of primary melanomas underlying the corresponding lesional skin in the same patients. Table IV provides representative examples of 6 primary melanomas and 6 nevus controls with full concordance reference consensus diagnoses. Fig 3, A, demonstrates that patient-derived melanoma xenografts express LINC and PRAME in a fashion comparable with primary cutaneous melanoma samples obtained via adhesive patch biopsies (Fig 3, B). Similarly, analyses of melanoma lymph node metastases also demonstrated detectable levels of LINC and PRAME in all 5 cases tested (data not shown).

In addition, we also investigated the test's performance and ability to differentiate primary melanomas from nonmelanoma skin lesions relative to histopathology. We compared the sensitivity of the primary pathology read with the consensus diagnosis of our 3-person dermatopathology expert panel using the same comparison used to assess the test. Using the expert reads as the standard, the primary reader's sensitivity was 89% (confidence interval 81%-94%) and the primary reader's specificity was 91% (confidence interval 87%-94%, $P < .001$, kappa 0.78).

DISCUSSION

Distinguishing melanomas from nevi based purely on noninvasive methods using pattern recognition, including gross assessment, dermoscopic assessment, or use of computerized pattern recognition tools, can be challenging. Many studies demonstrate a biopsy ratio of greater than 30 benign lesions for every 1 melanoma.⁹ Even computerized assessment and expert dermoscopic assessment may only result in a ratio of 8 to 1. This study demonstrates that gene expression analysis performed on stratum corneum samples collected using an adhesive patch biopsy can detect melanomas in the appropriate lesional type with an adequate sensitivity and specificity to contribute to the current standard of care and potentially significantly improve the ratio of benign to malignant lesions.

Although LINC and PRAME are of known importance in melanoma and other tumor types and prior studies by this group identified these 2 genes' transcripts in primary pigmented lesion samples,^{6,7} this is the first study to our knowledge to demonstrate a combined use of these 2 genes for optimized and robust pigmented lesion classification (ie, the 2-gene PLA). Through microarray studies, we initially identified 312 genes that were differentially

Table II. Performance of LINC00518 and/or preferentially expressed antigen in melanoma detection in the training set

Biology of sample	Pathologically confirmed	Neither of the 2 genes detected	1 of the 2 genes (LINC or PRAME) detected	Both LINC and PRAME detected	Detection (95% CI)
Melanoma	80	7	8	65	91%, Sensitivity* (83%-96%)
Nonmelanoma	77	41	25	11	53%, Specificity [†] (42%-65%)
Total	157				

CI, Confidence interval; LINC, LINC00518; PRAME, preferentially expressed antigen in melanoma.

*Number of melanoma samples where one or both LINC and PRAME are detected/total melanoma samples $\times 100$.

[†]Number of nonmelanoma samples where none of the LINC and PRAME are detected/total nonmelanoma samples $\times 100$.

Table III. Performance of LINC00518 and/or preferentially expressed antigen in melanoma detection in the validation set

Biology of sample	Pathologically confirmed	Neither of the 2 genes detected	1 of the 2 genes (LINC or PRAME) detected	Both LINC and PRAME detected	Detection (95% CI)
Melanoma	87	8	13	66	91%, Sensitivity (83%-96%)
Nonmelanoma	311	215	63	33	69%, Specificity (64%-74%)
Total	398				

CI, Confidence interval; LINC, LINC00518; PRAME, preferentially expressed antigen in melanoma.

expressed between primary cutaneous melanomas and nonmelanoma lesions, such as nevi. A 17-gene classifier able to discriminate between melanoma and nonmelanoma with a high degree of accuracy was developed.⁶ Analyses using custom array and qRT-PCR technologies indicated that 2-gene subsets of the original 17-gene classifier could provide a similar ability to separate melanoma from nonmelanoma samples with high levels of accuracy. LINC (Long Intergenic Non-Protein Coding RNA 518) and CMIP (c-Maf inducing protein) and LINC and PRAME (preferentially expressed antigen in melanoma) were the best performing gene pairs driving all separation. PRAME outperformed CMIP in larger data sets establishing the current optimized PLA that no longer requires preamplification steps. Low quantity-not-sufficient rates of 14% for frozen samples in this study and 9% for samples from ongoing clinical efforts where samples are shipped at ambient temperature by courier and processed without the need for freezing underscore the robustness of the approach.

The performance of this 2-gene LINC and PRAME assay using adhesive patch biopsy samples at a cost comparable with the histopathology gold standard is similar to a recently reported more complex algorithmic 23-gene postinvasive biopsy assay (90% sensitivity, 91% specificity) that also includes PRAME as a key target gene.⁵ However, the clinical use is quite different. The previously mentioned 23-gene assay is used to assess excised specimens with histopathologic uncertainty. Although the PLA can also be used in conjunction with follow-up surgical

histopathology to provide additional information about gene expression, many clinicians may choose to use the PLA on lesions they or the patient did not want to biopsy and that would have otherwise been observed and reassessed with serial clinical or dermoscopic photography at a follow-up visit. The noninvasive nature of tissue collection with adhesive patch biopsy not only favors what most patients prefer, but also offers further advantages for patients with wound-healing issues related to vascular disease, diabetes, or advanced age. It also provides further advantages to patients with lesions in cosmetically sensitive areas or who are anticoagulated and have a tendency to develop hypertrophic scars. Because the assay uses only 2 genes for pigmented lesion classification, cost of analysis and turnaround time of the assay is greatly reduced, and need for computer algorithmic data interpretation is avoided.

Although histopathology is the gold standard, it is associated with considerable interrater variability. This is well documented in current dermatopathology literature. In more extreme cases, diagnostic discordance as high as 38% between dermatopathologists was reported.¹⁰ Brochez et al² demonstrated in a large study involving 20 pathologists that their overall performance of correctly diagnosing melanomas histopathologically reached a sensitivity of 87%. The results of the PLA assay may be of further assistance in cases in which there is histologic uncertainty.²

Other prebiopsy tools that help improve physician performance and guide decisions of dermatology practitioners to biopsy a pigmented lesion

Table IV. Expression of LINC00518 and preferentially expressed antigen in melanoma in corresponding samples from adhesive patch biopsy specimens (patch samples) and surgically obtained biopsy specimens (FFPE samples) of the same primary cutaneous melanomas and the same nevi (n = 6 per group)

Sample ID	Concordance pathology	Sample type	LINC expression	PRAME expression	Test result
8542	Melanoma	Patch	Detected	Detected	Positive
		FFPE	Not detected	Detected	Positive
8612	Melanoma	Patch	Detected	Not detected	Positive
		FFPE	Detected	Not detected	Positive
9019	Melanoma	Patch	Detected	Detected	Positive
		FFPE	Detected	Detected	Positive
9023	Melanoma	Patch	Detected	Detected	Positive
		FFPE	Detected	Detected	Positive
9025	Melanoma	Patch	Detected	Detected	Positive
		FFPE	Detected	Detected	Positive
9061	Melanoma	Patch	Detected	Detected	Positive
		FFPE	Detected	Detected	Positive
8523	Nevus	Patch	Not detected	Not detected	Negative
		FFPE	Detected	Detected	Positive
8550	Nevus	Patch	Not detected	Not detected	Negative
		FFPE	Not detected	Detected	Positive
8580	Nevus	Patch	Not detected	Not detected	Negative
		FFPE	Not detected	Not detected	Negative
8583	Nevus	Patch	Not detected	Not detected	Negative
		FFPE	Not detected	Not detected	Negative
8601	Nevus	Patch	Not detected	Not detected	Negative
		FFPE	Not detected	Not detected	Negative
8611	Nevus	Patch	Not detected	Not detected	Negative
		FFPE	Not detected	Not detected	Negative

LINC, LINC00518; PRAME, preferentially expressed antigen in melanoma.

The reference was established via concordance diagnosis of 3 expert dermatopathologists (100% agreement on the diagnosis).

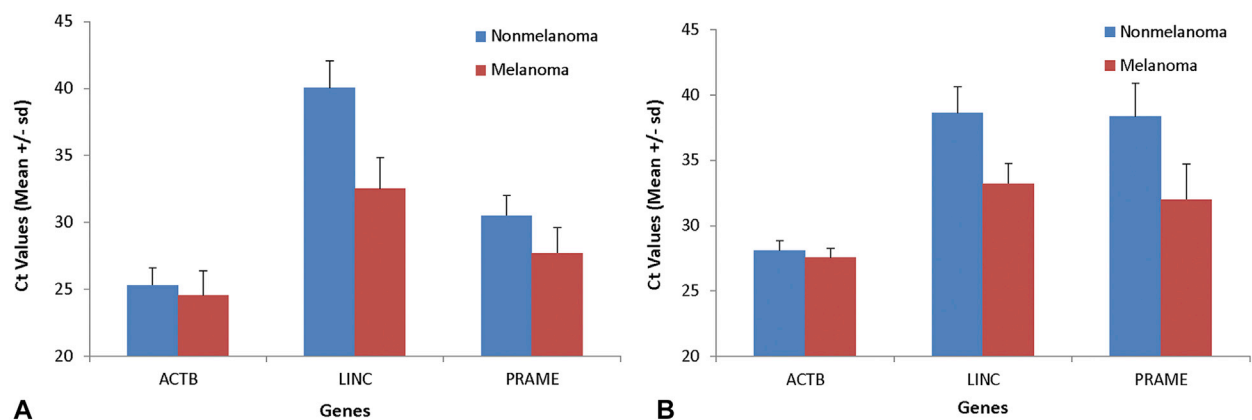


Fig 3. Comparison of LINC00518 (*LINC*), actin B (*ACTB*) and preferentially expressed antigen in melanoma (*PRAME*) gene expression in patient-derived melanoma xenografts (*PDX*) compared with nonmelanoma xenografts (**A**), and in adhesive patch samples of primary cutaneous melanomas processed with the *PDX* samples as controls (**B**). *Ct*, Cycle threshold.

include dermoscopy (both without and with bio-informatic support), imaging devices such as MelaFind (MELA Sciences, Irvington, NY), and impedance spectroscopy (Nevisense, Scibase, Stockholm, Sweden). Clinical decisions, supported

by tools or not, are inherently linked to a trade-off where most often a higher sensitivity (to minimize the risk of missing melanomas) is chosen at the cost of a lower specificity (inevitably linked to a higher rate of potentially avoidable invasive biopsies).¹¹

Reader studies often prove useful in monitoring clinical utility. A recent article reports a sensitivity and specificity of 71% and 59%, respectively, for dermatology practitioners familiar with the use of dermoscopy; the sensitivity of the also-reported decision tree classifier to score dermoscopic images was 96% and the specificity was at 43%, lower than the clinician's specificity.¹¹ A similar study using computer vision reported a sensitivity of 86% and a specificity of 52%.¹² The impedance spectroscopy device Nevisense (Scibase) showed a sensitivity of 97% and a specificity of 34%. Nevisense (Scibase) reads seborrheic keratoses as positive.¹³ MelaFind (MELA Sciences) is a multispectral imaging device approved by the Food and Drug Administration for the early detection of melanoma that exemplifies the trade-off mentioned above. MelaFind (MELA Sciences) has a high sensitivity of 98% but a low specificity of only about 10%.¹⁴ The specificity of these tools does not solve the problem of excessive numbers of biopsies seen as part of the current standard of care.¹⁵

In summary, we report that the accurate and objective detection of LINC and/or PRAME gene expression without the need for complex algorithms using a noninvasive adhesive patch biopsy may facilitate the assessment of pigmented lesions for melanoma. This technology may also help overcome diagnostic limitations inherently linked to visual image and pattern recognition widely used by clinicians and dermatopathologists.

We gratefully acknowledge the contributions of Michael Walker and Bob Schmidt (Walker Bioscience) on statistical analysis of the data; John Alsobrook's (DermTech Inc) contributions on work with metastatic tumors and xenografts; and help provided by Kamaryn Peters (DermTech Inc) on coordinating the study and administrative support. We also thank Christina Lee (Northwestern University) for help with manuscript preparation and submission and Drs Hansen, Gross, Scheinberg, and Mraz on behalf of our group of clinical site investigators.

REFERENCES

1. van der Rhee JI, Bergman W, Kukutsch NA. The impact of dermoscopy on the management of pigmented lesions in everyday clinical practice of general dermatologists: a prospective study. *Br J Dermatol*. 2010;162:563-567.
2. Brochez L, Verhaeghe E, Grosshans E, et al. Inter-observer variation in the histopathological diagnosis of clinically suspicious pigmented skin lesions. *J Pathol*. 2002;196:459-466.
3. Ohsie SJ, Sarantopoulos GP, Cochran AJ, Binder SW. Immunohistochemical characteristics of melanoma. *J Cutan Pathol*. 2008;35:433-444.
4. Gerami P, Cook RW, Russell MC, et al. Gene expression profiling for molecular staging of cutaneous melanoma in patients undergoing sentinel lymph node biopsy. *J Am Acad Dermatol*. 2015;72:780-785.e3.
5. Clarke LE, Warf BM, Flake DD II, et al. Clinical validation of a gene expression signature that differentiates benign nevi from malignant melanoma. *Journal Cutan Pathol*. 2015;42:244-252.
6. Wachsman W, Morhenn V, Palmer T, et al. Noninvasive genomic detection of melanoma. *Br J Dermatol*. 2011;164:797-806.
7. Gerami P, Alsobrook JP II, Palmer TJ, Robin HS. Development of a novel noninvasive adhesive patch test for the evaluation of pigmented lesions of the skin. *J Am Acad Dermatol*. 2014;71:237-244.
8. Carlson P, Ricono J, Mullins C, Broudy T, Mirsaidi C, Nair P. Establishment of patient-derived xenograft (PDX) models for small cell lung cancer (SCLC) as a preclinical platform for drug development [abstract]. Proceedings of the 105th Annual Meeting of the American Association for Cancer Research; April 7, 2014; San Diego, CA.
9. Hansen C, Wilkinson D, Hansen M, Argenziano G. How good are skin cancer clinics at melanoma detection? Number needed to treat variability across a national clinic group in Australia. *J Am Acad Dermatol*. 2009;61:599-604.
10. Farmer ER, Gonin R, Hanna MP. Discordance in the histopathologic diagnosis of melanoma and melanocytic nevi between expert pathologists. *Hum Pathol*. 1996;27:528-531.
11. Ferris LK, Harkes JA, Gilbert B, et al. Computer-aided classification of melanocytic lesions using dermoscopic images. *J Am Acad Dermatol*. 2015;73:769-776.
12. Zortea M, Schopf TR, Thon K, et al. Performance of a dermoscopy-based computer vision system for the diagnosis of pigmented skin lesions compared with visual evaluation by experienced dermatologists. *Artif Intell Med*. 2014;60:13-26.
13. Malvey J, Hauschild A, Curiel-Lewandrowski C, et al. Clinical performance of the Nevisense system in cutaneous melanoma detection: an international, multicenter, prospective and blinded clinical trial on efficacy and safety. *Br J Dermatol*. 2014;171:1099-1107.
14. Monheit G, Cagnetta AB, Ferris L, et al. The performance of MelaFind: a prospective multicenter study. *Arch Dermatol*. 2011;147:188-194.
15. Cukras AR. On the comparison of diagnosis and management of melanoma between dermatologists and MelaFind. *JAMA Dermatol*. 2013;149:622-623.

Supplemental Table I. Dermatopathologic diagnoses of validation set samples

	Validation subgroup A (N = 195)	Validation subgroup B (N = 203)
Melanomas	63	24
Invasive melanomas	42	11
In situ melanomas	8	11
Invasive/in situ melanomas*	13	2
Nevi	113	140
Conventional nevi	29	19
Dysplastic nevi	58	119
Conventional/dysplastic nevi [†]	26	2
Other nonmelanoma diagnoses [‡]	19	39

The validation set was composed of archival samples (validation subgroup A, n = 195) and serially collected samples (validation subgroup B, n = 203).

*Diagnosed as melanoma by 3 dermatopathologists without full agreement on the invasive/in situ nature of the sample.

[†]Diagnosed as nevus by 3 dermatopathologists without full agreement on presence or absence of dysplasia.

[‡]Includes seborrheic keratosis, lentigo simplex, basal cell carcinoma, and fibrosis.

Supplemental Table II. Performance of LINC00518 and/or preferentially expressed antigen in melanoma detection in the validation set groups

Sample lot	Biology of sample	Pathologically confirmed	Neither of the 2 genes detected	1 of the 2 genes (LINC or PRAME) detected	Both LINC and PRAME detected	Detection (95% CI)
Archival	Melanoma	63	3	8	52	95%, Sensitivity (87%-99%)
	Nonmelanoma	132	72	36	24	55%, Specificity (46%-63%)
	Total	195				
Serial	Melanoma	24	5	5	14	79%, Sensitivity (58%-93%)
	Nonmelanoma	179	143	27	9	80%, Specificity (73%-85%)
	Total	203				

CI, Confidence interval; LINC, LINC00518; PRAME, preferentially expressed antigen in melanoma.